

## Parinaud oculoglandular syndrome

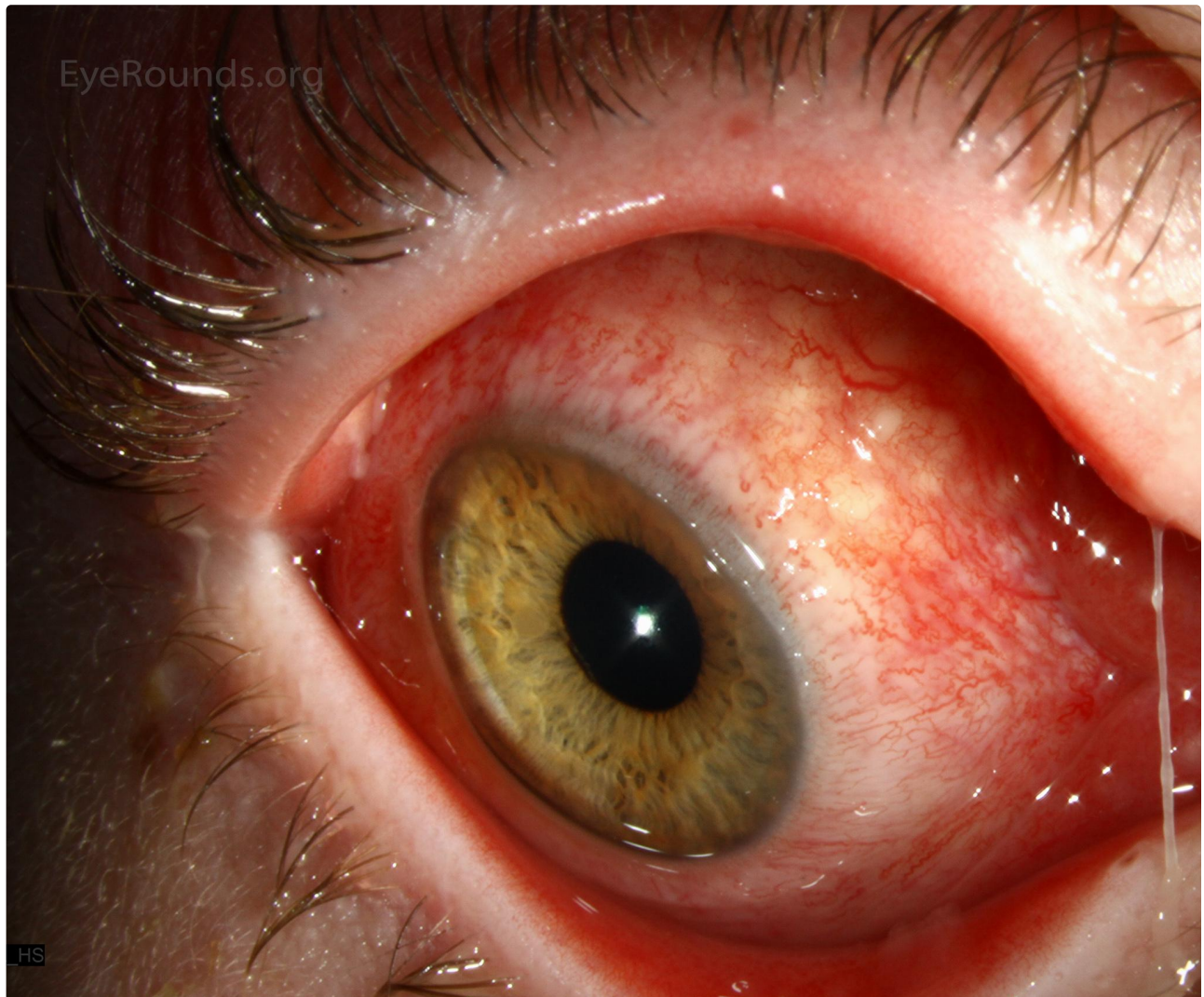
Category(ies): Cornea

Contributor: [Jesse Vislisel, MD](#)

Photographer: Brice Critser, CRA

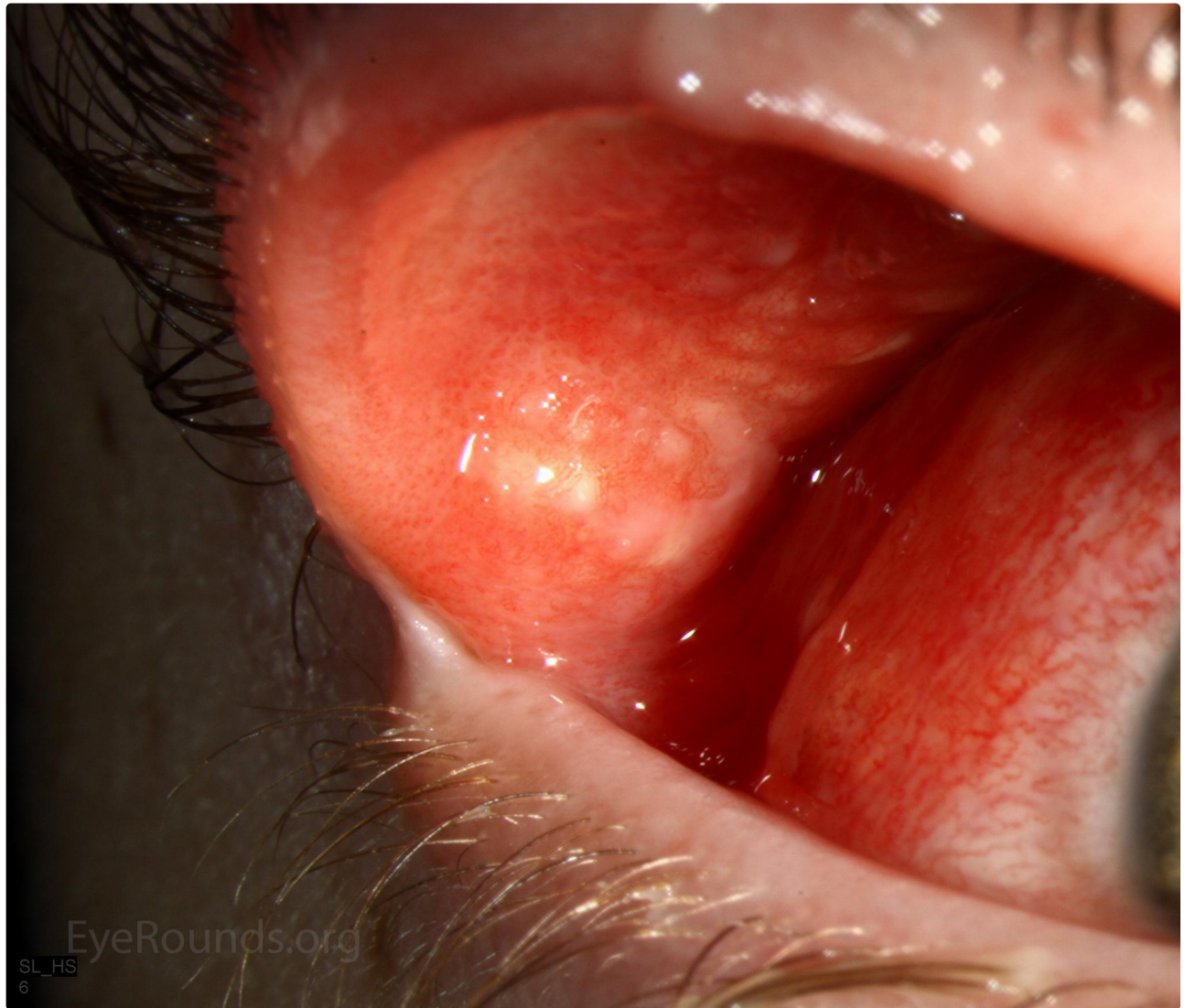

Parinaud oculoglandular syndrome is a unilateral granulomatous conjunctivitis with regional lymphadenopathy. The most common identifiable cause is *Bartonella henselae* (cat scratch disease), but less common etiologies include *Afipia felis*, *Bartonella clarridgeiae*, tularemia, tuberculosis, sporotrichosis, syphilis, and coccidiomycosis.



 Enlarge

 Download



 Enlarge

 Download

**Image Permissions:**



Ophthalmic Atlas Images by [EyeRounds.org](http://EyeRounds.org), [The University of Iowa](http://The University of Iowa) are licensed under a [Creative Commons Attribution-NonCommercial-NoDerivs 3.0 Unported License](http://creativecommons.org/licenses/by-nc-nd/3.0/).

## Address

University of Iowa  
Roy J. and Lucille A. Carver College  
of Medicine  
Department of Ophthalmology and  
Visual Sciences  
200 Hawkins Drive  
Iowa City, IA 52242

[Support Us](#)

## Legal

Copyright © 2019 The University of  
Iowa. All Rights Reserved  
[Report an issue with this page](#)  
[Web Privacy Policy](#) |  
[Nondiscrimination Statement](#)

## Related Links

[Cataract Surgery for Greenhorns](#)  
[EyeTransillumination](#)  
[Gonioscopy.org](#)  
[Iowa Glaucoma Curriculum](#)  
[Iowa Wet Lab](#)  
[Patient Information](#)  
[Stone Rounds](#)  
[The Best Hits Bookshelf](#)

## EyeRounds Social Media

Follow



Receive notification of new cases,  
[sign up here](#)  
[Contact Us](#)  
[Submit a Suggestion](#)